

**Intravitreal bevacizumab injection in a 14-year-old Vogt-Koyanagi-Harada patient with choroidal neovascular membrane**

Vogt-Koyanagi-Harada syndrome is a bilateral granulomatous panuveitis with central nervous system, auditory, and integumentary manifestations.<sup>1,2</sup> Typically, ocular involvement is associated with choroidal lesions, exudative retinal detachments, and optic nerve inflammation.<sup>2</sup> Treatment usually requires high-dose systemic corticosteroids and immunosuppressive agents.<sup>1,2</sup> Resolution without visually significant sequelae may occur, but complications, including cataract, glaucoma, and choroidal neovascular membrane formation, are not infrequent.<sup>1</sup>

A 14-year-old male patient presented to Maghrabi Eye Hospital, Jeddah, Saudi Arabia, in May 2006 with a history of blurry vision and headaches. There was no history of systemic illnesses. Visual acuity was 20/50 OU initially. Biomicroscopic examination revealed +2 cells and +1 flare in the anterior chamber, +2 vitreous cells, bilateral exudative retinal detachment, and congested optic nerves. On the basis of these findings a diagnosis of Vogt-Koyanagi-Harada syndrome was made, and treatment was initiated with oral and topical administration of corticosteroids and cycloplegics. Visual acuity improved to 20/25 OD and 20/20 OS the following month. The patient was thereafter followed in King Abdulaziz University Hospital, Jeddah, Saudi Arabia. After control of the inflammation, steroids were tapered over 3 months with subsequent recurrence. Methotrexate was introduced after consultation with rheumatologists and increased to 15 mg/week with no control of the inflammation; thus cyclosporin followed by infliximab was introduced.

Visual acuity remained stable until July 2008, by which

time a choroidal neovascular membrane (CNVM) had developed, reducing the patient's visual acuity to counting fingers OS over a month (Fig. 1A). Fluorescein angiography showed an area of expanding hyperfluorescence with late leakage in the subfoveal location in the left eye (Fig. 1B). Optical coherence tomography confirmed the presence of a subfoveal CNVM with a central retinal thickness of 268  $\mu\text{m}$  (Fig. 1C).

After informed consent had been obtained, 1.25 mg

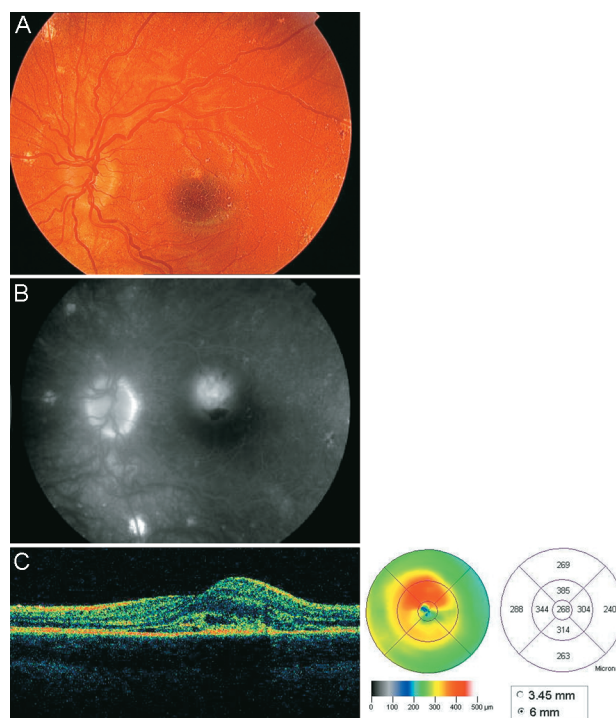


Fig. 1—Choroidal neovascular membrane before avastin injection.

intravitreal bevacizumab was injected twice, 6 weeks apart, in the left eye. After the second injection, the patient's best-corrected visual acuity improved to 20/40 on day 2 and 20/20 on day 9; fundus photography illustrates the regression of the CNVM (Fig. 2A). Fluorescein angiography confirmed a reduction in leakage (Fig. 2B). The central retinal thickness had reached 201  $\mu\text{m}$  at 4 weeks (Fig. 2C).

Choroidal neovascular membranes can cause severe visual impairment and present a major challenge in management. Argon laser treatment shows a drop in visual acuity with high rates of recurrence and persistence.<sup>3</sup> Photodynamic therapy has been tried, with worsening of the visual acuity in the majority of cases. Poor success and high recurrence rates have been seen after submacular surgery for removal of CNVM.<sup>4</sup>

Bevacizumab is a full-length monoclonal antibody directed against all active forms of vascular endothelial

growth factor (VEGF). Recently, VEGF has been implicated in the pathogenesis of CNVM, and thus bevacizumab has been used to treat CNVM due to age-related macular degeneration.<sup>5</sup>

A literature review using MEDLINE has failed to reveal any mention of a case of CNVM in children with Vogt-Koyanagi-Harada syndrome treated with intravitreal bevacizumab. This case illustrates that intravitreal bevacizumab has a possible role in the treatment of the condition with regression of neovascular membrane and subsequent visual improvement, although a large prospective study and a longer follow-up is required to reach a conclusive result.

The authors have no proprietary or commercial interest in any materials discussed in this article.

## REFERENCES

1. Foster CS, Vitale AT. *Diagnosis and Treatment of Uveitis*. Philadelphia, Penn.: W.B. Saunders Company; 2002.
2. Liesegang TJ. Vogt Koyanagi Harada. *Basic and Clinical Science Course (BCSC) Section 9: Intraocular Inflammation and Uveitis*. American Academy of Ophthalmology. 2008:209–21.
3. Persistent and recurrent neovascularization after laser photocoagulation for subfoveal choroidal neovascularization of age-related macular degeneration. Macular Photocoagulation Study Group. *Arch Ophthalmol* 1994;112:462–4.
4. Thomas MA, Dickinson JD, Melberg NS, Ibanez HE, Dhaliwal RS. Visual results after surgical removal of subfoveal choroidal neovascular membranes. *Ophthalmology* 1994;101:1384–96.
5. Bashshur ZF, Bazarbachi A, Schakal A, Haddad ZA, El Haibi CP, Nouredin BN. Intravitreal bevacizumab for the management of choroidal neovascularization in age-related macular degeneration. *Am J Ophthalmol* 2006;142:1–9.

**Lina Raffa, Ahmed Bawazeer**

King Abdulaziz University Hospital, Jeddah, Saudi Arabia

Correspondence to Ahmed Bawazeer, MD: drbawazeer@yahoo.com

*Can J Ophthalmol* 2009;44:615–6

doi:10.3129/i09-144

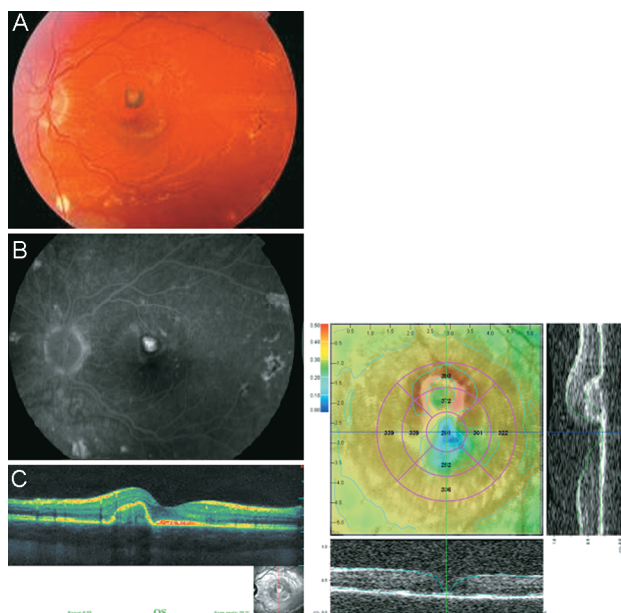


Fig. 2—Shrinkage of the choroidal neovascular membrane post avastin injection.